

DynaMed Plus®

DynaMed Plus® is updated multiple times each day and provides current, evidence-based information to support decision making at the point of care.

Why *DynaMed Plus*?

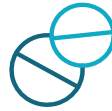- **Evidence-Based Content:** *DynaMed Plus* includes easy-to-interpret levels of evidence labels so users can quickly determine the quality of the evidence.
- **Access Everywhere:** *DynaMed Plus* can be accessed anywhere including online, in the EHR, through the HL7 Infobutton, and from a mobile device.
- **Recent Updates:** Newly added evidence can be viewed right from the home page and updates can be filtered by specialty.
- **Easy-to-Find Information:** *DynaMed Plus* is designed so users can quickly find answers to their clinical questions. Topics include an Overview and Recommendation section for high-level review, and the table of contents helps users take a deeper dive into the evidence.



What will I find in *DynaMed Plus*?



Updated
24x7x365



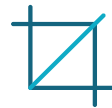Micromedex®
Drug Content



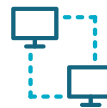Evidence-Based
Recommendations



Alerts When Topics
Change



Graphics and
Images



Easy Access
From EHRs




One-Click Access to
Full-Text Articles



Mobile App

The Right Answers, Every Time



DynaMed Plus®

EBSCO Health

Content, Features and Functionality at a Glance...

EBSCOHealth Calculators

DynaMed Plus COPD Search

2

1

3

4

5

Search Within Text

Overview and Recommendations

Related Summaries

General Information

Epidemiology

Etiology and Pathogenesis

History and Physical

Diagnosis

Treatment

Complications and Prognosis

Prevention and Screening

Quality Improvement

Guidelines and Resources

Patient Information

ICD-9/ICD-10 Codes

References

COPD

Follow Print E-mail CME

Updates

[+] Updated 2017 Jul 27 03:58 PM (ET)

ACP Produced in collaboration with the American College of Physicians

Recommendations Editor Allen Shaughnessy, PharmD, M Med Ed, FCCP

Deputy Editor Terence Trow, MD, FACP, FCCP

Overview and Recommendations

Background

- Chronic obstructive pulmonary disease (COPD) is characterized by significant airflow limitation associated with a chronic inflammatory response in the airways and lungs resulting in the destruction of lung tissue.
 - It commonly affects adults > 40 years old who smoke, with an estimated worldwide prevalence of 4%-10%.
 - The disease course is usually progressive with a long-term decline in lung function and is the third leading cause of mortality worldwide.
- Smoking is the most common risk factor for COPD worldwide; other risk factors include occupational exposures (for example, organic and inorganic dusts, chemical agents, and fumes), alpha-1 antitrypsin deficiency, and indoor air pollution (particularly from biomass smoke caused from burning biomass fuels in confined spaces).
- COPD has several complications, including acute exacerbation, respiratory failure, and pulmonary hypertension.
- 4-year mortality rates range from 28% for mild-to-moderate COPD to 62% for moderate-to-severe COPD.

EBSCOHealth Calculators

DynaMed Plus COPD Search

8

6

7

Search Within Text

Overview and Recommendations

Related Summaries

General Information

Epidemiology

Etiology and Pathogenesis

History and Physical

Diagnosis

Making the diagnosis

Differential diagnosis

Testing overview

Blood tests

Imaging studies

Chest x-ray

Computed tomography (CT)

Biopsy and pathology

Pulmonary function tests

Other diagnostic testing

Treatment

Complications and Prognosis

COPD

Follow Print E-mail CME

Diagnosis / Imaging studies / Chest x-ray

- Saber-sheath trachea (trachea normal to level of thoracic inlet, then narrows in coronal plane)
- increased retrosternal airspace (> 2.5 cm between sternum and ascending aorta)
- increased length of lung (> 30 cm)
- increased rib space
 - bullae
 - signs of arterial deficiency in outer lung fields
- reduced number and size of pulmonary vessels and branches
- vessels distorted and may have increased branching angles
- References - (1) COPD 2007 Jun;4(2):143 Host Full Text full-text

Computed tomography (CT)

- computed tomography not usually recommended except⁽¹⁾
 - in patients with
 - suspected bronchiectasis or lung cancer
 - planned surgical procedure, including lung volume reduction or lung transplant
 - for detecting comorbidities

CC-20 chest CT: This chest CT scan shows multiple sharply defined areas of low attenuation, characteristic of centrilobular emphysema. Paraseptal emphysema and bullae are seen in the subpleural lung regions. Such findings, with an appropriate history and pulmonary function abnormalities, are consistent with a diagnosis of COPD. Abbreviations: CT, computed tomography; COPD, chronic obstructive pulmonary disease.

Bullae on chest CT: Bullae appear as hyperlucent areas on CT, sharply demarcated from surrounding lung by a thin wall. Here the bullae have caused compressive atelectasis of the right lower lobe and a leftward shift of the mediastinum. Abbreviation: CT, computed tomography.

- 1 Currency**
The date of the most recent update and the source of evidence is always displayed at the top of the topic.
- 2 Follow Feature**
Quickly and easily set up alerts to be notified when topics are updated.
- 3 Authors and Editors**
Click on authors and editors to learn more about their credentials.
- 4 Recommendations**
Concise, evidence-based recommendations with supporting references and GRADE classifications.
- 5 Easy Navigation**
Search within a topic or navigate using the linked table of contents.
- 6 PubMed Links**
Easily access the PubMed citation for the original article and full text when available.
- 7 Visual Content**
Images, algorithms and other visual content are included in topics where relevant.
- 8 Provide Feedback**
Click the feedback button to send comments about a topic right to the editorial team.